

Non-immunological Contact Urticaria (NICU) due to Ethanol Containing Hand Sanitiser: A Case Report

SHASHANK BANSOD¹, BHUSHAN MADKE²

ABSTRACT

Contact Urticaria (CU) is a wheal and flare reaction, occurring within few minutes to hours of contact to an external agent over skin or mucosa. Depending on underlying pathophysiology, CU is of two types: immunological CU and non-immunological CU. Use of hand sanitisers has increased multifold in this COVID-19 pandemic, due to increased awareness regarding maintaining a good hygiene to reduce the transmission of infection. This present case is a 24-year-old man, who overzealously added ethanol-based hand sanitiser to his bathing water on the advice of a general physician and after bathing developed redness, swelling and itching on various body parts. A diagnosis of Non-immunological CU (NICU) due to ethanol in sanitiser was made, based on history and clinical examination.

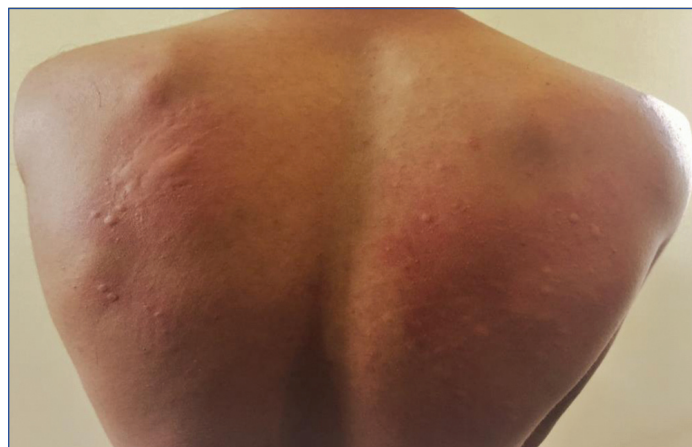Keywords: Adverse cutaneous reaction, Autoimmune urticaria, COVID-19, Prostaglandins, Urticaria

CASE REPORT

A 24-year-old male student, presented to in a private Dermatology Clinic with a present illness, history of redness, swelling and itching over back, chest, both arms and both legs since morning after taking bath. Detailed history revealed that the patient had added a full bottle of 200 mL of hand sanitiser to bathing water in order to sanitise his whole body, considering the situation of COVID-19 outbreak. Immediately after bathing, the patient developed generalised burning sensation followed by eruption of itchy wheals on various body parts. There was no significant personal, family, medical or drug intake history.

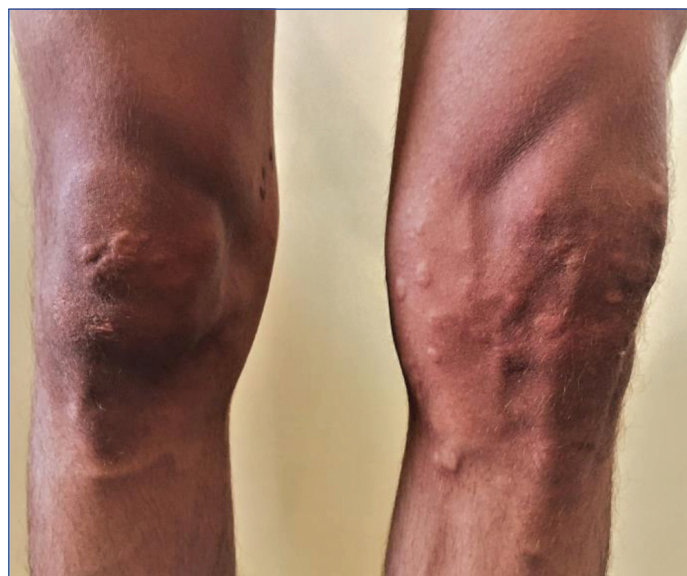The patient consulted a general practitioner who prescribed him oral antihistamine-cetirizine and oral antibiotic-cefixime. However, the patient did not have any relief.

On examination, there were multiple urticarial wheals of different sizes ranging from approximately 1 cm in diameter to as large as 10 cm, which were distributed unevenly all over the body, having erythematous base at some places. The lesions were firm to touch, non-blanchable and non-tender on pressure [Table/Fig-1,2].



[Table/Fig-1]: Multiple wheals of varied sizes and shapes with the background of erythema can be seen all over the back particularly distributed over scapular area.

Based on the history, physical examination and no response to antihistamines, a diagnosis of NICU due to ethanol-based hand sanitiser was made. This patient received low dose of



[Table/Fig-2]: Multiple wheals of varied sizes without much erythema can be seen over both legs in asymmetric fashion mostly present around the knees and shin.

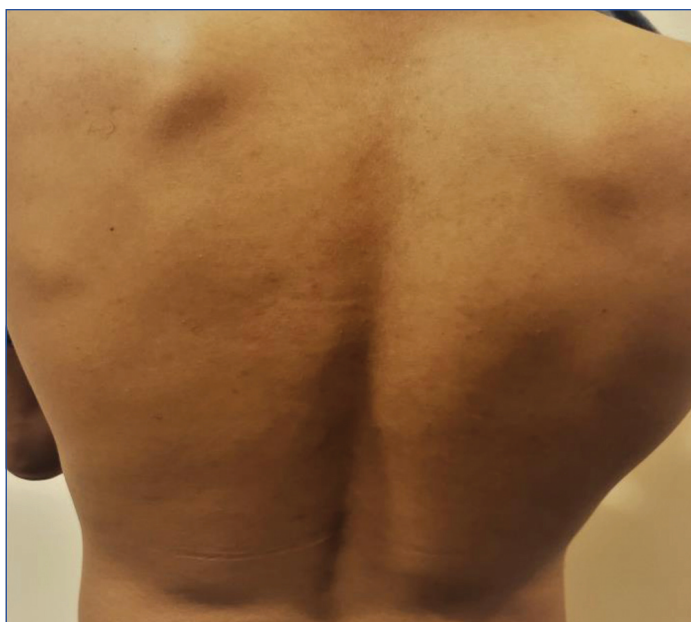oral aspirin 75 mg twice a day and clobetasol ointment for local application to be applied twice a day. The patient reported significant improvement with reduction in itching and burning with resolution of wheals on next follow-up after three days [Table/Fig-3,4].

DISCUSSION

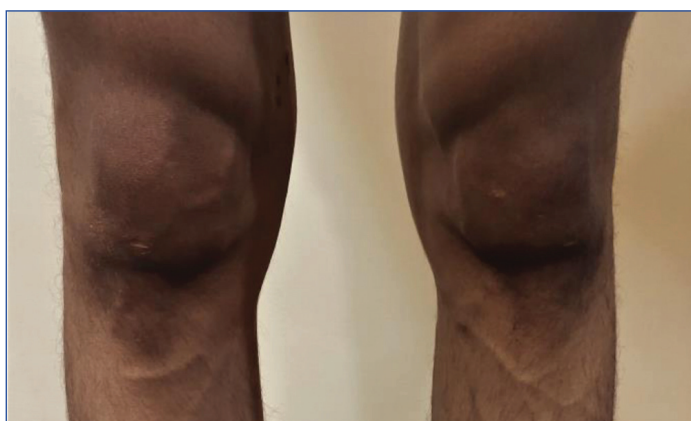
The chemical compound ethanol, also known as ethyl alcohol is a bio alcohol used in various industries including beverage, pharmaceuticals and most recently as a fuel. When ingested chronically above normal limits, it may increase risk for liver cirrhosis [1].

Recently, with advent of COVID-19, the use of ethanol in hand sanitisers has gained much importance. Alcohol including ethanol in concentration of 70-90% has been shown to have a good antimicrobial effect against nearly all the pathogens except the protozoan oocytes, bacterial spores and some viruses [2].

On the downside, recurrent use of ethanol in sanitisers may also cause contact irritant reactions and allergic reactions, presenting as symptoms ranging from dry, itchy, scaly palms



[Table/Fig-3]: All the wheals over back disappeared after treatment.



[Table/Fig-4]: All the wheals over lower both legs disappeared after treatment.

to erythematous, scaly, pruritic plaques and patches of various sizes [3].

CU is one of the reactions encountered by the use of hand sanitiser which presents as a wheal and flare response to ethanol when it comes in contact with skin and mucosa [4]. Usual symptoms start with raised erythematous swelling over skin, which is pruritic and may or may not progress to generalised reaction and anaphylaxis [5,6]. It was first discovered by Alexander Fischer in 1973, and its symptoms last for less than six weeks [3].

The prevalence of CU is unrecognised due to low disease diagnosis rate. The disease is more common than it is reported. Non-immunological CU is more common than immunological.

The stages of progression of CU range from initial wheal and flare reaction with non-specific symptoms, to anaphylactic shock, as depicted below in [Table/Fig-5], stages of progression of CU [6,7]:

Contact urticaria (CU) is of two types:

1) Immunological; 2) Non-immunological

| Stage | Description |
|-------|---|
| 1. | Localised reaction (redness and swelling) with non-specific symptoms (burning, itching, tingling) |
| 2. | Generalised reaction |
| 3. | Extracutaneous symptoms (rhinoconjunctivitis, orolaryngeal and gastrointestinal dysfunction) |
| 4. | Anaphylactic shock |

[Table/Fig-5]: Stages of progression of Contact Urticaria (CU).

In Immunological CU, prior sensitisation of eliciting substance is required. Here an antigen binds to IgE specific antibody on dermal mast cells resulting in release of histamine and vasoactive amines causing disturbances in skin microcirculation (Type 1 hypersensitivity) [6] it is diagnosed by history, clinical examination and if required, in-vitro and in-vivo skin tests are done. Treatment includes avoidance of offending agent, H1 antihistamine, oral steroids, phototherapy and immunosuppressants [4,5].

NICU occurs without any prior exposure to eliciting substance. Symptoms develop within minutes to hours and remain till 24 hours, but may vary depending on site of exposure.

This type of urticaria do not go beyond stage 1 (Localised reaction). The severity of symptoms depends on the site of exposure, the concentration of offending agent and mode of exposure.

Probable pathophysiology involves prostaglandins released from epidermis while other proposed mechanisms include direct capillary damage at contact site, leading to release of vasoactive amines, leukotrienes and acetylcholine.

In this case, the patient developed local reaction all over body, as he had added causative agent, ethanol (200 mL hand sanitiser) to bathing water, which was then poured all over the body. Soon after the bath, he developed localised reaction of wheal and flare along with non-specific symptoms of itching and burning. The lesions did not progress beyond stage 1.

Wilkin JK and Fortner G first reported immediate urticarial response after patch test with lower alcohols and aldehydes [8], which were followed by more studies stating CU [9,10] and dermatitis [11] by ethanol.

The diagnosis of NICU is based on detailed history and clinical examination only. Extensive laboratory work-up is not required. However, open test/skin provocation test is used for the diagnosis of ICU. Our diagnosis of due to ethanol in sanitiser was based on the following facts: a) Immediate reaction of wheal and flare following bathing, not progressing beyond stage 1, after bathing with water containing 70% ethanol; b) No previous history of urticaria in the patient; c) No response to antihistamines. As prostaglandins play a major role in the pathogenesis, oral Acetyl Salicylic Acid (ASA) and NSAIDs are first line of treatment; while oral corticosteroid is the second line of treatment. UVA and UVB light have shown to inhibit NICU reaction; effect can last up to two weeks after treatment. This patient received tab. aspirin 75 mg twice a day and clobetasol ointment for local application.

CONCLUSION(S)

NICU is a common entity, more common than immunological CU. So, while treating urticaria, a physician should be watchful of this condition, especially when the patient does not respond to antihistamines.

REFERENCES

- [1] Gold NA, Mirza TM, Avva U. Alcohol Sanitiser. [Updated 2020 Jun 24]. In: Stat Pearls [Internet]. Treasure Island (FL): Stat Pearls Publishing; 2020.
- [2] Jain VM, Karibasappa GN, Dodamani AS, Prashanth VK, Mali GV. Comparative assessment of antimicrobial efficacy of different hand sanitizers: An in-vitro study. Dent Res J (Isfahan). 2016;13(5):424-31.
- [3] Vethachalam S, Persaud Y. Contact Urticaria. [Updated 2019 Nov 9]. In: StatPearls [Internet]. Treasure Island (FL): StatPearls Publishing; 2020.
- [4] Fisher AA. Contact dermatitis. Philadelphia: Lea and Fibiger; 1973.
- [5] Poona Walla T, Kelly B. Urticaria: A review. Am J Clin Dermatol. 2009;10:09-21.
- [6] Bhatia R, Alikhan A, Maibach HI. Contact urticaria: Present scenario. Indian J Dermatol. 2009;54:264-68.
- [7] Maibach HI, Johnson HL. Contact urticaria syndrome. Contact urticaria to diethyltoluamide (immediate-type hypersensitivity). Arch Dermatol. 1975;111:726-30.
- [8] Wilkin JK, Fortner G. Cutaneous vascular sensitivity to lower aliphatic alcohols and aldehydes in Orientals. Alcohol Clin Exp Res. 1985;9:522-25.
- [9] Davari P, Maibach HI. Contact urticaria to cosmetic and industrial dyes. Clin Exp Dermatol. 2011;36:01-05.

- [10] WHO Guidelines on Hand Hygiene in Health Care: First Global Patient Safety Challenge Clean Care Is Safer Care. 14, Skin reactions related to hand hygiene. Geneva: World Health Organization; 2009.
- [11] Bosker HM, Politiek K, Urgert MC, Flach PA, Coenraads PJ, Schuttelaar ML. Occupational allergic contact dermatitis caused by 1-propanol in a hand disinfectant. *Contact Dermatitis*. 2017;76:241-43.

PARTICULARS OF CONTRIBUTORS:

1. Doctor, Consultant Dermatologist, Department of Dermatology, Hi-Tech Skin Clinic and Hair Transplant Centre, Nagpur, Maharashtra, India.
2. Professor and Head, Department of Dermatology, Venereology and Leprosy, Jawaharlal Nehru Medical College, Datta Meghe Institute of Medical Sciences, Sawangi Meghe, Wardha, Maharashtra, India.

NAME, ADDRESS, E-MAIL ID OF THE CORRESPONDING AUTHOR:

Dr. Shashank Bansod,
Doctor, Consultant Dermatologist, Department of Dermatology, Hi-Tech Skin Clinic and Hair Transplant Centre, Vijay Bhawan, Opposite Lokmat Building, Dhantoli, Nagpur, Maharashtra, India.
E-mail: hitech.skin@yahoo.com

PLAGIARISM CHECKING METHODS: [\[Jain H et al.\]](#)

- Plagiarism X-checker: Jul 25, 2020
- Manual Googling: Nov 03, 2020
- iThenticate Software: Dec 18, 2020 (5%)

ETYMOLOGY: Author Origin**AUTHOR DECLARATION:**

- Financial or Other Competing Interests: None
- Was informed consent obtained from the subjects involved in the study? NA
- For any images presented appropriate consent has been obtained from the subjects. Yes

Date of Submission: **Jul 19, 2020**Date of Peer Review: **Oct 14, 2020**Date of Acceptance: **Nov 07, 2020**Date of Publishing: **Jan 01, 2021**